



ISREE: case of the month

December 2020: Getting inked



This case of the month follows a missed tattoo used to identify a malignant lesion during colonoscopy, resulting in extended duration of colonic resection.

Here's a snapshot of the learning points:

Endoscopic lesion mis-localisation can have important implications on subsequent surgery or endoscopic surveillance.

Steps to ensure appropriate tattooing practice should be followed.

Deviation from standardised practice can ultimately lead to intra-operative changes to management or unnecessary repeat procedures

Case synopsis

A middle-aged patient underwent a colonoscopy for change in bowel habit and altered blood in his stool. A lesion suspicious for cancer was identified in the ascending colon and biopsies were taken. Two tattoos were placed on the anal side of the lesion and a staging CT scan was arranged. The scan did not identify the lesion in question and showed no evidence of spread. Biopsies revealed a cancer.

The patient's case was discussed in the local multidisciplinary team (MDT) meeting and they were listed for a laparoscopic right hemicolectomy. On the day of their operation, all notes, scans and MDT discussions were reviewed by the operating surgeon and the team. The endoscopy report read '2 tattoos placed distal to lesion in ascending colon'. Only photos of the lesion were seen. The report commented on poor bowel preparation limiting some views.

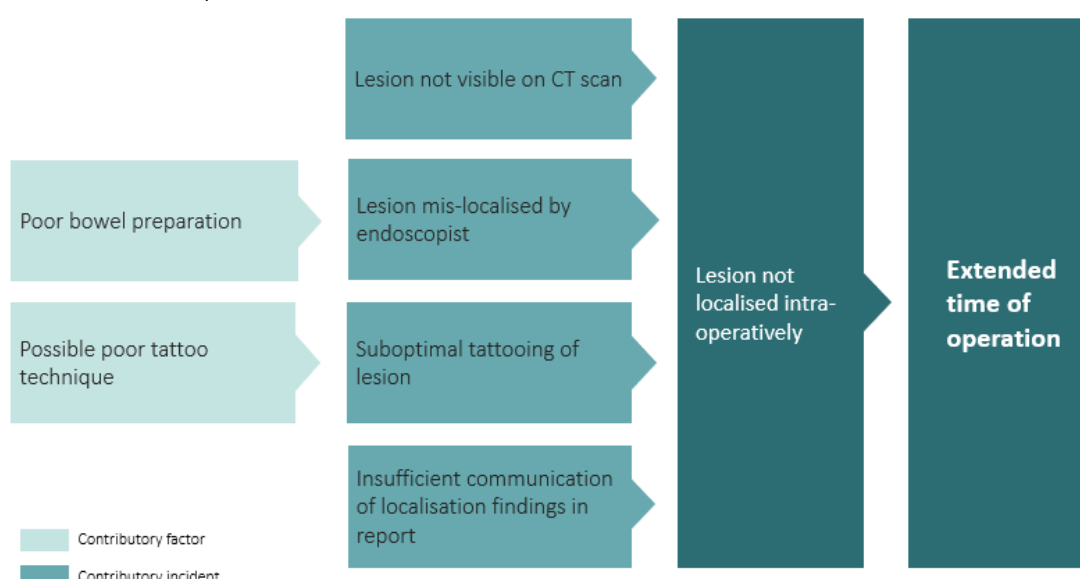
Following laparoscope insertion, a detailed examination of the bowel did not show any evidence of a tattoo. The operation proceeded and a right hemicolectomy was performed to include the area described in the endoscopy report, as per the MDT plan.

Given the lack of tattoo, the surgical consultant and assisting trainee examined the resected colon and could not identify any evidence of the malignant lesion. An on-table colonoscopy was performed which identified the cancer in the distal transverse colon, just proximal to the splenic flexure. No tattoos were evident and this area was further tattooed.

The operation was converted to an open laparotomy and resection was extended to include the lesion. This led to a greater operative and bowel-handling time than originally planned.

Safety incidents and contributory factors

Below is a visual representation of this case. We have highlighted the incidents involved and their contributory factors:



Learning

This case highlights the importance of endoscopic lesion localisation in the operative patient pathway. Here are some learning points to consider:


Lesion localisation

- Accurate localisation of lesions at colonoscopy can be challenging and has consequences on subsequent surgical management.
- Adjuncts such as scope position guides and pre-endoscopy cross-sectional imaging decrease the likelihood of lesion mis-localisation.
- Bowel preparation may hinder accurate lesion identification and localisation and areas of concern may need to be reassessed through position change or repeat procedures.

Tattoo practice

In this case, tattooing practice at index colonoscopy may have been suboptimal. We've outlined some steps that may be helpful:

<p>Decision When to tattoo</p>	<ul style="list-style-type: none"> • Tattooing guides surgical resection and endoscopic surveillance strategies. • <u>Tattooing should be done for lesions > 20mm or suspected malignancy</u> (outside of caecum and rectum). • Don't tattoo in the rectum – this can cause staining of the mesorectum and impact significantly on surgical management.
<p>Technique How to tattoo</p>	<p>Delivery</p> <ul style="list-style-type: none"> • A <u>potential reason for invisible tattoos</u> is superficial delivery. • It is widespread practice now <u>to raise a saline bleb before switching to tattoo</u> – this ensures the tattoo is placed in the submucosal space (ie not too superficial or deep). <p>Number</p> <ul style="list-style-type: none"> • For marking polyps or resection sites, it is acceptable to place a single tattoo • For cancers, 3-4 tattoos should ideally be placed in a circumferential method to improve intra-operative visualisation of tattoos. (<u>Pohl</u> and <u>Kethu</u>) <p>Location</p> <ul style="list-style-type: none"> • Generally, tattooing 2-5cm anal to a lesion is preferable. • Tattoos can be placed <u>immediately anal to a lesion margin</u> to aid specific localisation. However, it may be sensible to place tattoos further away to prevent tumour cell seeding. • For lesions that can be endoscopically resected, this also limits the risk of submucosal fibrosis or muscle injury during subsequent resection.
<p>Report How to report tattooing</p>	<p>When reporting tattooing, the following should be documented:</p> <ul style="list-style-type: none"> • The exact tattoo location should be stated relative to the lesion, including the distance from the lesion. Use 'anal' or 'caecal' side rather than 'proximal' or 'distal' to describe site, to avoid confusion. • The exact number of tattoos placed. • If more than one set of tattoos, explicit description of relative location to any lesions should be documented.
<p>Monitor Monitoring tattooing practice</p>	<ul style="list-style-type: none"> • Ideally services should have a tattoo policy and audit practice regularly.



What are your views on this case? Continue the discussion online @JAG_Endoscopy #COTM

Have you had any learning points with similar experiences that you wish to share with our endoscopy community? Contact askjag@rcplondon.ac.uk for more information.